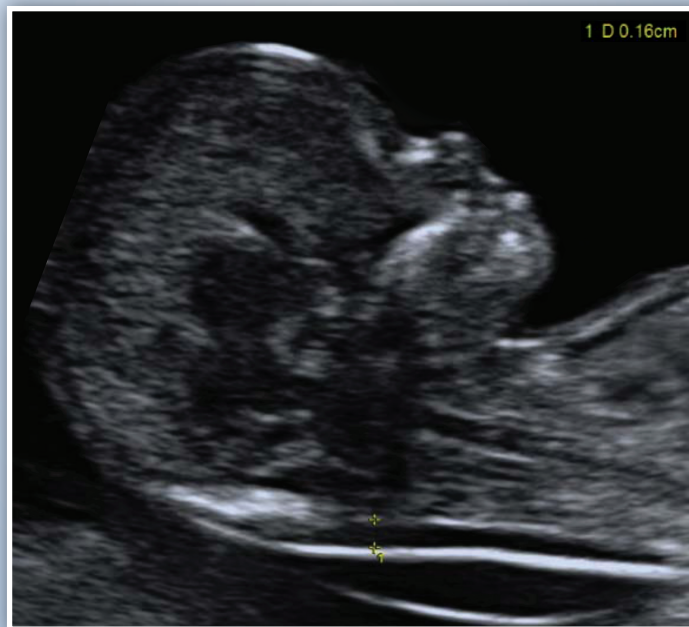

AIUM Practice Parameter for the Performance of

Obstetric Ultrasound Examinations

Parameter developed in conjunction with the American College of Radiology (ACR), the American College of Obstetricians and Gynecologists (ACOG), and the Society of Radiologists in Ultrasound (SRU).



The association for medical ultrasound
aium[®]
AMERICAN INSTITUTE OF ULTRASOUND IN MEDICINE

© 2013 by the American Institute of Ultrasound in Medicine

The American Institute of Ultrasound in Medicine (AIUM) is a multi-disciplinary association dedicated to advancing the safe and effective use of ultrasound in medicine through professional and public education, research, development of parameters, and accreditation.

To promote this mission, the AIUM is pleased to publish, in conjunction with the American College of Radiology (ACR), the American College of Obstetricians and Gynecologists (ACOG), and the Society of Radiologists in Ultrasound (SRU), this *AIUM Practice Parameter for the Performance of Obstetric Ultrasound Examinations*. We are indebted to the many volunteers who contributed their time, knowledge, and energy to bringing this document to completion.

The AIUM represents the entire range of clinical and basic science interests in medical diagnostic ultrasound, and, with hundreds of volunteers, the AIUM has promoted the safe and effective use of ultrasound in clinical medicine for more than 50 years. This document and others like it will continue to advance this mission.

Practice parameters of the AIUM are intended to provide the medical ultrasound community with parameters for the performance and recording of high-quality ultrasound examinations. The parameters reflect what the AIUM considers the minimum criteria for a complete examination in each area but are not intended to establish a legal standard of care. AIUM-accredited practices are expected to generally follow the parameters with recognition that deviations from these parameters will be needed in some cases, depending on patient needs and available equipment. Practices are encouraged to go beyond the parameters to provide additional service and information as needed.



14750 Sweitzer Ln, Suite 100
Laurel, MD 20707-5906 USA
800-638-5352 • 301-498-4100
www.aium.org

I. Introduction

The clinical aspects contained in specific sections of this parameter (Introduction, Classification of Fetal Sonographic Examinations, Specifications of the Examination, Equipment Specifications, and Fetal Safety) were revised collaboratively by the American Institute of Ultrasound in Medicine (AIUM), the American College of Radiology (ACR), the American College of Obstetricians and Gynecologists (ACOG), and the Society of Radiologists in Ultrasound (SRU). Recommendations for personnel qualifications, written request for the examination, procedure documentation, and quality control vary among the organizations and are addressed by each separately.

This parameter has been developed for use by practitioners performing obstetric sonographic studies. Fetal ultrasound^a should be performed only when there is a valid medical reason, and the lowest possible ultrasonic exposure settings should be used to gain the necessary diagnostic information.^{1,2} A limited examination may be performed in clinical emergencies or for a limited purpose such as evaluation of fetal or embryonic cardiac activity, fetal position, or amniotic fluid volume. A limited follow-up examination may be appropriate for reevaluation of fetal size or interval growth or to reevaluate abnormalities previously noted if a complete prior examination is on record.

While this parameter describes the key elements of standard sonographic examinations in the first trimester and second and third trimesters, a more detailed anatomic examination of the fetus may be necessary in some cases, such as when an abnormality is found or suspected on the standard examination or in pregnancies at high risk for fetal anomalies. In some cases, other specialized examinations may be necessary as well.

While it is not possible to detect all structural congenital anomalies with diagnostic ultrasound, adherence to the following parameters will maximize the possibility of detecting many fetal abnormalities.

II. Classification of Fetal Sonographic Examinations

A. First-Trimester Examination

A standard obstetric sonogram in the first trimester includes evaluation of the presence, size, location, and number of gestational sac(s). The gestational sac is examined for the presence of a yolk sac and embryo/fetus. When an embryo/fetus is detected, it should be measured and cardiac activity recorded by a 2-dimensional video clip or M-mode imaging. Use of spectral Doppler imaging is discouraged. The uterus, cervix, adnexa, and cul-de-sac region should be examined.

^a The consensus of the committee was that the use of the terms *ultrasound* and *sonography* is at the discretion of each organization.

B. Standard Second- or Third-Trimester Examination

A standard obstetric sonogram in the second or third trimester includes an evaluation of fetal presentation, amniotic fluid volume, cardiac activity, placental position, fetal biometry, and fetal number, plus an anatomic survey. The maternal cervix and adnexa should be examined as clinically appropriate when technically feasible.

C. Limited Examination

A limited examination is performed when a specific question requires investigation. For example, in most routine nonemergency cases, a limited examination could be performed to confirm fetal heart activity in a bleeding patient or to verify fetal presentation in a laboring patient. In most cases, limited sonographic examinations are appropriate only when a prior complete examination is on record.

D. Specialized Examinations

A detailed anatomic examination is performed when an anomaly is suspected on the basis of the history, biochemical abnormalities, or the results of either the limited or standard scan. Other specialized examinations might include fetal Doppler ultrasound, a biophysical profile, a fetal echocardiogram, and additional biometric measurements.

III. Qualifications and Responsibilities of Personnel

See the AIUM Official Statement *Training Guidelines for Physicians Who Evaluate and Interpret Diagnostic Abdominal, Obstetric, and/or Gynecologic Ultrasound Examinations* and the AIUM *Standards and Guidelines for the Accreditation of Ultrasound Practices*.

IV. Written Request for the Examination

The written or electronic request for an ultrasound examination should provide sufficient information to allow for the appropriate performance and interpretation of the examination.

The request for the examination must be originated by a physician or other appropriately licensed health care provider or under the provider's direction. The accompanying clinical information should be provided by a physician or other appropriate health care provider familiar with the patient's clinical situation and should be consistent with relevant legal and local health care facility requirements.

V. Specifications of the Examination

A. First-Trimester Ultrasound Examination

1. Indications

Indications for first-trimester^b sonography include but are not limited to:

- a. Confirmation of the presence of an intrauterine pregnancy³⁻⁵;
- b. Evaluation of a suspected ectopic pregnancy^{6,7};
- c. Defining the cause of vaginal bleeding;
- d. Evaluation of pelvic pain;
- e. Estimation of gestational (menstrual)^c age;
- f. Diagnosis or evaluation of multiple gestations;
- g. Confirmation of cardiac activity;
- h. Imaging as an adjunct to chorionic villus sampling, embryo transfer, and localization and removal of an intrauterine device;
- i. Assessing for certain fetal anomalies, such as anencephaly, in high-risk patients;
- j. Evaluation of maternal pelvic masses and/or uterine abnormalities;
- k. Measuring the nuchal translucency (NT) when part of a screening program for fetal aneuploidy; and
- l. Evaluation of a suspected hydatidiform mole.

Comment

A limited examination may be performed to evaluate interval growth, estimate amniotic fluid volume, evaluate the cervix, and assess the presence of cardiac activity.

2. Imaging Parameters

Comment

Scanning in the first trimester may be performed either transabdominally or transvaginally. If a transabdominal examination is not definitive, a transvaginal scan or transperineal scan should be performed whenever possible.⁸

- a. The uterus (including the cervix) and adnexa should be evaluated for the presence of a gestational sac. If a gestational sac is seen, its location should be documented. The gestational sac should be evaluated for the presence or absence of a yolk sac or embryo, and the crown-rump length should be recorded when possible.⁹

^b For the purpose of this document, first trimester represents 1 week to 13 weeks 6 days.

^c For the purpose of this document, the terms *gestational age* and *menstrual age* are considered equivalent.

Comment

A definitive diagnosis of intrauterine pregnancy can be made when an intrauterine gestational sac containing a yolk sac or embryo/fetus with cardiac activity is visualized. A small, eccentric intrauterine fluid collection with an echogenic rim can be seen before the yolk sac and embryo are detectable in a very early intrauterine pregnancy. In the absence of sonographic signs of ectopic pregnancy, the fluid collection is highly likely to represent an intrauterine gestational sac. In this circumstance, the intradecidual sign may be helpful.¹⁰ Follow-up sonography and/or serial determination of maternal serum human chorionic gonadotropin levels are/is appropriate in pregnancies of undetermined location to avoid inappropriate intervention in a potentially viable early pregnancy.

The crown-rump length is a more accurate indicator of gestational (menstrual) age than is the mean gestational sac diameter. However, the mean gestational sac diameter may be recorded when an embryo is not identified.

Caution should be used in making the presumptive diagnosis of a gestational sac in the absence of a definite embryo or yolk sac. Without these findings, an intrauterine fluid collection could represent a pseudo-gestational sac associated with an ectopic pregnancy.

- b. The presence or absence of cardiac activity should be documented with a 2-dimensional video clip or M-mode imaging.

Comment

With transvaginal scans, while cardiac motion is usually observed when the embryo is 2 mm or greater in length, if an embryo less than 7 mm in length is seen without cardiac activity, a subsequent scan in 1 week is recommended to ensure that the pregnancy is nonviable.^{4,5,11-13}

- c. Fetal number should be documented.

Comment

Amnionicity and chorionicity should be documented for all multiple gestations when possible.

- d. Embryonic/fetal anatomy appropriate for the first trimester should be assessed.
- e. The nuchal region should be imaged, and abnormalities such as cystic hygroma should be documented.

Comment

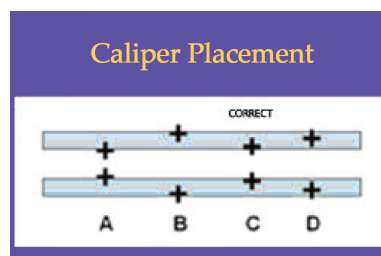
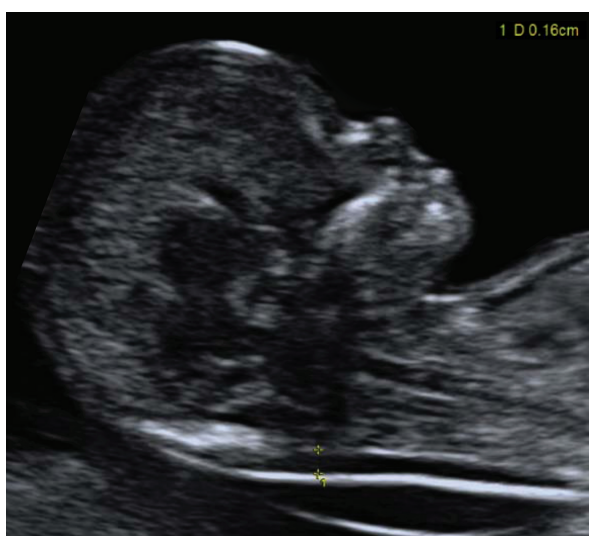For those patients desiring to assess their individual risk of fetal aneuploidy, a very specific measurement of the NT during a specific age interval is necessary (as determined by the laboratory used). See the parameters for this measurement below.

NT measurements should be used (in conjunction with serum biochemistry) to determine the risk of having a fetus with aneuploidy or other anatomic abnormalities such as heart defects.

In this setting, it is important that the practitioner measure the NT according to established parameters for measurement. A quality assessment program is recommended to ensure that false-positive and false-negative results are kept to a minimum.^{14,15}

Parameters for NT Measurement:

- i. The margins of the NT edges must be clear enough for proper placement of the calipers.
- ii. The fetus must be in the midsagittal plane.
- iii. The image must be magnified so that it is filled by the fetal head, neck, and upper thorax.
- iv. The fetal neck must be in a neutral position, not flexed and not hyperextended.
- v. The amnion must be seen as separate from the NT line.
- vi. The + calipers on the ultrasound must be used to perform the NT measurement.
- vii. Electronic calipers must be placed on the inner borders of the nuchal line space with none of the horizontal crossbar itself protruding into the space.
- viii. The calipers must be placed perpendicular to the long axis of the fetus.
- viii. The measurement must be obtained at the widest space of the NT.



- f. The uterus including the cervix, adnexal structures, and cul-de-sac should be evaluated. Abnormalities should be imaged and documented.

Comment

The presence, location, appearance, and size of adnexal masses should be documented. The presence and number of leiomyomata should be documented. The measurements of the largest or any potentially clinically significant leiomyomata should be documented. The cul-de-sac should be evaluated for the presence or absence of fluid. Uterine anomalies should be documented.

B. Second- and Third-Trimester Ultrasound Examination^{16–18}

1. Indications

Indications for second- and third-trimester sonography include but are not limited to:

- a. Screening for fetal anomalies^{19–22};
- b. Evaluation of fetal anatomy;
- c. Estimation of gestational (menstrual) age;
- d. Evaluation of fetal growth;
- e. Evaluation of vaginal bleeding;
- f. Evaluation of abdominal or pelvic pain;
- g. Evaluation of cervical insufficiency;
- h. Determination of fetal presentation;
- i. Evaluation of suspected multiple gestation;
- j. Adjunct to amniocentesis or other procedure;
- k. Evaluation of a significant discrepancy between uterine size and clinical dates;
- l. Evaluation of a pelvic mass;
- m. Evaluation of a suspected hydatidiform mole;
- n. Adjunct to cervical cerclage placement;
- o. Suspected ectopic pregnancy;
- p. Suspected fetal death;
- q. Suspected uterine abnormalities;
- r. Evaluation of fetal well-being;
- s. Suspected amniotic fluid abnormalities;
- t. Suspected placental abruption;
- u. Adjunct to external cephalic version;
- v. Evaluation of premature rupture of membranes and/or premature labor;

- w. Evaluation of abnormal biochemical markers;
- x. Follow-up evaluation of a fetal anomaly;
- y. Follow-up evaluation of placental location for suspected placenta previa;
- z. History of previous congenital anomaly;
- aa. Evaluation of the fetal condition in late registrants for prenatal care; and
- bb. Assessment for findings that may increase the risk for aneuploidy.

Comment

In certain clinical circumstances, a more detailed examination of fetal anatomy may be indicated.

2. Imaging Parameters for a Standard Fetal Examination²³

- a. Fetal cardiac activity, fetal number, and presentation should be documented.

Comment

An abnormal heart rate and/or rhythm should be documented.

Multiple gestations require the documentation of additional information: chorionicity, amnionicity, comparison of fetal sizes, estimation of amniotic fluid volume (increased, decreased, or normal) in each gestational sac, and fetal genitalia (when visualized).

- b. A qualitative or semiquantitative estimate of amniotic fluid volume should be documented.

Comment

Although it is acceptable for experienced examiners to qualitatively estimate amniotic fluid volume, semiquantitative methods have also been described for this purpose (eg, amniotic fluid index, single deepest pocket, and 2-diameter pocket).²⁴

- c. The placental location, appearance, and relationship to the internal cervical os should be documented. The umbilical cord should be imaged and the number of vessels in the cord documented. The placental cord insertion site²⁵ should be documented when technically possible.^{26–28}

Comment

It is recognized that the apparent placental position early in pregnancy may not correlate well with its location at the time of delivery.

Transabdominal, transperineal, or transvaginal views may be helpful in visualizing the internal cervical os and its relationship to the placenta.

Transvaginal or transperineal ultrasound may be considered if the cervix appears shortened or cannot be adequately visualized during the transabdominal sonogram.^{29,30}

A velamentous (also called membranous) placental cord insertion that crosses the internal os of the cervix is vasa previa, a condition that has a high risk of fetal mortality if not diagnosed before labor.^{31–33}

d. Gestational (menstrual) age assessment.^{12,13}

First-trimester crown-rump measurement is the most accurate means for sonographic dating of pregnancy. Beyond this period, a variety of sonographic parameters such as biparietal diameter, abdominal circumference, and femoral diaphysis length can be used to estimate gestational (menstrual) age. The variability of gestational (menstrual) age estimation, however, increases with advancing pregnancy. Significant discrepancies between gestational (menstrual) age and fetal measurements may suggest the possibility of a fetal growth abnormality, intrauterine growth restriction, or macrosomia.³⁴

Comment

The pregnancy should not be redated after an accurate earlier scan has been performed and is available for comparison.

- i. The biparietal diameter is measured at the level of the thalami and cavum septi pellucidi or columns of the fornix. The cerebellar hemispheres should not be visible in this scanning plane. The measurement is taken from the outer edge of the proximal skull to the inner edge of the distal skull.

Comment

The head shape may be flattened (dolichocephaly) or rounded (brachycephaly) as a normal variant. Under these circumstances, certain variants of normal fetal head development may make measurement of the head circumference more reliable than biparietal diameter for estimating gestational (menstrual) age.

- ii. The head circumference is measured at the same level as the biparietal diameter, around the outer perimeter of the calvarium. This measurement is not affected by head shape.
- iii. The femoral diaphysis length can be reliably used after 14 weeks' gestational (menstrual) age. The long axis of the femoral shaft is most accurately measured with the beam of insonation being perpendicular to the shaft, excluding the distal femoral epiphysis.
- iv. The abdominal circumference or average abdominal diameter should be determined at the skin line on a true transverse view at the level of the junction of the umbilical vein, portal sinus, and fetal stomach when visible.

Comment

The abdominal circumference or average abdominal diameter measurement is used with other biometric parameters to estimate fetal weight and may allow detection of intrauterine growth restriction or macrosomia.

e. Fetal weight estimation.

Fetal weight can be estimated by obtaining measurements such as the biparietal diameter, head circumference, abdominal circumference or average abdominal diameter, and femoral diaphysis length. Results from various prediction models can be compared to fetal weight percentiles from published nomograms.^{35,36}

Comment

If previous studies have been performed, appropriateness of growth should also be documented. Scans for growth evaluation can typically be performed at least 2 to 4 weeks apart. A shorter scan interval may result in confusion as to whether measurement changes are truly due to growth as opposed to variations in the technique itself.^{37,38}

Currently, even the best fetal weight prediction methods can yield errors as high as $\pm 15\%$. This variability can be influenced by factors such as the nature of the patient population, the number and types of anatomic parameters being measured, technical factors that affect the resolution of ultrasound images, and the weight range being studied.

f. Maternal anatomy.

Evaluation of the uterus, adnexal structures, and cervix should be performed when appropriate. If the cervix cannot be visualized, a transperineal or transvaginal scan may be considered when evaluation of the cervix is needed.^{29,30}

Comment

This will allow recognition of incidental findings of potential clinical significance. The presence, location, and size of adnexal masses and the presence of at least the largest and potentially clinically significant leiomyomata should be documented. It is not always possible to image the normal maternal ovaries during the second and third trimesters.

g. Fetal anatomic survey.

Fetal anatomy, as described in this document, may be adequately assessed by ultrasound after approximately 18 weeks' gestational (menstrual) age. It may be possible to document normal structures before this time, although some structures can be difficult to visualize due to fetal size, position, movement, abdominal scars, and increased maternal abdominal wall thickness.³⁹ A second- or third-trimester scan may pose technical limitations for an anatomic evaluation due to imaging artifacts from acoustic shadowing. When this occurs, the report of the sonographic examination should document the nature of this technical limitation. A follow-up examination may be helpful.

The following areas of assessment represent the minimal elements of a standard examination of fetal anatomy. A more detailed fetal anatomic examination may be necessary if an abnormality or suspected abnormality is found on the standard examination.

- i. Head, face, and neck:
 - Lateral cerebral ventricles;
 - Choroid plexus;
 - Midline falx;
 - Cavum septi pellucidi;
 - Cerebellum;
 - Cistern magna; and
 - Upper lip.

Comment

A measurement of the nuchal fold may be helpful during a specific age interval to assess the risk of aneuploidy.⁴⁰

- ii. Chest:
 - Heart^{41–43};
 - Four-chamber view;
 - Left ventricular outflow tract; and
 - Right ventricular outflow tract.
- iii. Abdomen:
 - Stomach (presence, size, and situs);
 - Kidneys;
 - Urinary bladder;
 - Umbilical cord insertion site into the fetal abdomen; and
 - Umbilical cord vessel number.

- iv. Spine:
Cervical, thoracic, lumbar, and sacral spine.
- v. Extremities:
Legs and arms.
- vi. Sex:
In multiple gestations and when medically indicated.

VI. Documentation

Adequate documentation is essential for high-quality patient care. There should be a permanent record of the ultrasound examination and its interpretation. Images of all appropriate areas, both normal and abnormal, should be recorded. Variations from normal size should be accompanied by measurements. Images should be labeled with the patient identification, facility identification, examination date, and side (right or left) of the anatomic site imaged. An official interpretation (final report) of the ultrasound findings should be included in the patient's medical record. Retention of the ultrasound examination should be consistent both with clinical needs and with relevant legal and local health care facility requirements.⁴⁴

Reporting should be in accordance with the *AIUM Practice Parameter for Documentation of an Ultrasound Examination*.

VII. Equipment Specifications

These studies should be conducted with real-time scanners, using a transabdominal and/or transvaginal approach. A transducer of appropriate frequency should be used. Real-time sonography is necessary to confirm the presence of fetal life through observation of cardiac activity and active movement.

The choice of transducer frequency is a trade-off between beam penetration and resolution. With modern equipment, 3- to 5-MHz abdominal transducers allow sufficient penetration in most patients while providing adequate resolution. A lower-frequency transducer may be needed to provide adequate penetration for abdominal imaging in an obese patient. During early pregnancy, a 5-MHz abdominal transducer or a 5- to 10-MHz or greater vaginal transducer may provide superior resolution while still allowing adequate penetration.

VIII. Fetal Safety

Diagnostic ultrasound studies of the fetus are generally considered safe during pregnancy.⁴⁵ This diagnostic procedure should be performed only when there is a valid medical indication, and the lowest possible ultrasonic exposure setting should be used to gain the necessary diagnostic information under the ALARA (as low as reasonably achievable) principle.^{46–48}

A thermal index for soft tissue (Tis) should be used at earlier than 10 weeks' gestation, and a thermal index for bone (Tib) should be used at 10 weeks' gestation or later when bone ossification is evident. In keeping with the ALARA principle, M-mode imaging should be used instead of spectral Doppler imaging to document embryonic/fetal heart rate.

The promotion, selling, or leasing of ultrasound equipment for making “keepsake fetal videos” is considered by the US Food and Drug Administration to be an unapproved use of a medical device.⁴⁹ Use of a diagnostic ultrasound system for these purposes, without a physician's order, may be in violation of state laws or regulations.⁴⁹

IX. Quality Control and Improvement, Safety, Infection Control, and Patient Education

Policies and procedures related to quality control, patient education, infection control, and safety should be developed and implemented in accordance with the *AIUM Standards and Guidelines for the Accreditation of Ultrasound Practices*.

Equipment performance monitoring should be in accordance with the *AIUM Standards and Guidelines for the Accreditation of Ultrasound Practices*.

X. ALARA Principle

The potential benefits and risks of each examination should be considered. The ALARA principle should be observed when adjusting controls that affect the acoustic output and by considering transducer dwell times. Further details on ALARA may be found in the AIUM publication *Medical Ultrasound Safety*, Third Edition.

Acknowledgments

This parameter was revised by the AIUM in collaboration with the American College of Radiology (ACR), the American College of Obstetricians and Gynecologists (ACOG), and the Society of Radiologists in Ultrasound (SRU) according to the process described in the *AIUM Clinical Standards Committee Manual*.

Collaborative Subcommittees

Members represent their societies in the initial version and final revision of this parameter.

AIUM

Jude Crino, MD
Harris J. Finberg, MD
Faith Frieden, MD

ACOG

Jeffrey Kuller, MD
Anthony Odibo, MD
Alfred Robichaux, MD

ACR

Marcela Bohm-Velez, MD, *Chair*
Dolores H. Pretorius, MD
Sheila Sheth, MD

SRU

Teresita L. Angtuaco, MD
Ulrike M. Hamper, MD, MBA
Barbara S. Hertzberg, MD

AIUM Clinical Standards Committee

Leslie Scoutt, MD, *Chair*

Joseph Wax, MD, *Vice Chair*

Bryann Bromley, MD

Lin Diacon, MD, RDMS, RPVI

J. Christian Fox, MD, RDMS

Pat Fulgham, MD

Charlotte Henningsen, MS, RT, RDMS, RVT

Adam Hiett, MD, RDMS

Lars Jensen, MD

Alexander Levitov, MD

Vicki Noble, MD, RDMS

Anthony Odibo, MD, MSCE

Deborah Rubens, MD

Khaled Sakhel, MD

Shia Salem, MD

Jay Smith, MD

Lami Yeo, MD

Original copyright 1985; revised 2013, 2007, 2003, 1996, 1994, 1991, 1990
Renamed 2015

References

1. Barnett SB, Ter Haar GR, Ziskin MC, Rott HD, Duck FA, Maeda K. International recommendations and guidelines for the safe use of diagnostic ultrasound in medicine. *Ultrasound Med Biol* 2000; 26:355–366.
2. Bly S, Van den Hof MC. Obstetric ultrasound biological effects and safety. *J Obstet Gynaecol Can* 2005; 27:572–580.
3. Barnhart K, van Mello NM, Bourne T, et al. Pregnancy of unknown location: a consensus statement of nomenclature, definitions, and outcome. *Fertil Steril* 2011; 95:857–866.
4. Jevc Y, Rana R, Bhide A, Thangaratinam S. Accuracy of first-trimester ultrasound in the diagnosis of early embryonic demise: a systematic review. *Ultrasound Obstet Gynecol* 2011; 38:489–496.
5. Thilaganathan B. The evidence base for miscarriage diagnosis: better late than never. *Ultrasound Obstet Gynecol* 2011; 38:487–488.
6. Chambers SE, Muir BB, Haddad NG. Ultrasound evaluation of ectopic pregnancy including correlation with human chorionic gonadotrophin levels. *Br J Radiol* 1990; 63:246–250.
7. Hill LM, Kislak S, Martin JG. Transvaginal sonographic detection of the pseudogestational sac associated with ectopic pregnancy. *Obstet Gynecol* 1990; 75:986–988.
8. Kirk E, Daemen A, Papageorgiou AT, et al. Why are some ectopic pregnancies characterized as pregnancies of unknown location at the initial transvaginal ultrasound examination? *Acta Obstet Gynecol Scand* 2008; 87:1150–1154.
9. Laing FC, Frates MC. Ultrasound evaluation during the first trimester of pregnancy. In: Callen PW (ed). *Ultrasonography in Obstetrics and Gynecology*. 4th ed. Philadelphia, PA: WB Saunders Co; 2000:105–145.
10. Chiang G, Levine D, Swire M, McNamara A, Mehta T. The intradecidual sign: is it reliable for diagnosis of early intrauterine pregnancy? *AJR Am J Roentgenol* 2004; 183:725–731.
11. Abdallah Y, Daemen A, Kirk E, et al. Limitations of current definitions of miscarriage using mean gestational sac diameter and crown-rump length measurements: a multicenter observational study. *Ultrasound Obstet Gynecol* 2011; 38:497–502.
12. Goldstein SR, Wolfson R. Endovaginal ultrasonographic measurement of early embryonic size as a means of assessing gestational age. *J Ultrasound Med* 1994; 13:27–31.
13. Robinson HP. Sonar measurement of fetal crown-rump length as means of assessing maturity in first trimester of pregnancy. *Br Med J* 1973; 4:28–31.
14. Snijders RJ, Noble P, Sebire N, Souka A, Nicolaides KH. UK multicentre project on assessment of risk of trisomy 21 by maternal age and fetal nuchal-translucency thickness at 10–14 weeks of gestation. Fetal Medicine Foundation First Trimester Screening Group. *Lancet* 1998; 352:343–346.
15. Wapner R, Thom E, Simpson JL, et al. First-trimester screening for trisomies 21 and 18. *N Engl J Med* 2003; 349:1405–1413.
16. Callen PW. The obstetric ultrasound examination. In: Callen PW (ed). *Ultrasonography in Obstetrics and Gynecology*. 4th ed. Philadelphia, PA: WB Saunders Co; 2000:1–17.
17. Garmel SH, D'Alton ME. Diagnostic ultrasound in pregnancy: an overview. *Semin Perinatol* 1994; 18:117–132.
18. Seeds JW. The routine or screening obstetrical ultrasound examination. *Clin Obstet Gynecol* 1996; 39:814–830.

19. American College of Obstetricians and Gynecologists. ACOG practice bulletin no. 27: clinical management guidelines for obstetrician-gynecologists. Prenatal diagnosis of fetal chromosomal abnormalities. *Obstet Gynecol* 2001; 97(suppl):1–12.
20. Bulas DI, Fonda JS. Prenatal evaluation of fetal anomalies. *Pediatr Clin North Am* 1997; 44:537–553.
21. Malone FD, Canick JA, Ball RH, et al. First-trimester or second-trimester screening, or both, for Down's syndrome. *N Engl J Med* 2005; 353:2001–2011.
22. Smith-Bindman R, Hosmer W, Feldstein VA, Deeks JJ, Goldberg JD. Second-trimester ultrasound to detect fetuses with Down syndrome: a meta-analysis. *JAMA* 2001; 285:1044–1055.
23. Salomon LJ, Alfirevic Z, Berghella V, et al. Practice guidelines for performance of the routine mid-trimester fetal ultrasound scan. *Ultrasound Obstet Gynecol* 2011; 37:116–126.
24. Magann EF, Sanderson M, Martin JN, Chauhan S. The amniotic fluid index, single deepest pocket, and two-diameter pocket in normal human pregnancy. *Am J Obstet Gynecol* 2000; 182:1581–1588.
25. Canadian Task Force on Preventive Health Care. New grades for recommendations from the Canadian Task Force on Preventive Health Care. *CMAJ* 2003; 169:207–208.
26. Harris RD, Cho C, Wells WA. Sonography of the placenta with emphasis on pathological correlation. *Semin Ultrasound CT MR* 1996; 17:66–89.
27. Pretorius DH, Chau C, Poeltler DM, Mendoza A, Catanzarite VA, Hollenbach KA. Placental cord insertion visualization with prenatal ultrasonography. *J Ultrasound Med* 1996; 15:585–593.
28. Sepulveda W, Rojas I, Robert JA, Schnapp C, Alcalde JL. Prenatal detection of velamentous insertion of the umbilical cord: a prospective color Doppler ultrasound study. *Ultrasound Obstet Gynecol* 2003; 21:564–569.
29. Mahony BS. Ultrasound of the cervix during pregnancy. *Abdom Imaging* 1997; 22:569–578.
30. Maymon R, Shulman A, Ariely S, Halperin R, Caspi E, Weinraub Z. Sonographic assessment of cervical changes during pregnancy and delivery: current concepts. *Eur J Obstet Gynecol Reprod Biol* 1996; 67:149–155.
31. Lee W, Lee VL, Kirk JS, Sloan CT, Smith RS, Comstock CH. Vasa previa: prenatal diagnosis, natural evolution, and clinical outcome. *Obstet Gynecol* 2000; 95:572–576.
32. Gagnon R, Morin L, Bly S, et al. Guidelines for the management of vasa previa. *J Obstet Gynaecol Can* 2009; 31:748–760.
33. Oyelese Y. Placenta previa and vasa previa: time to leave the Dark Ages. *Ultrasound Obstet Gynecol* 2001; 18:96–99.
34. Altman DG, Chitty LS. New charts for ultrasound dating of pregnancy. *Ultrasound Obstet Gynecol* 1997; 10:174–191.
35. Hadlock FP, Harrist RB, Carpenter RJ, Deter RL, Park SK. Sonographic estimation of fetal weight: the value of femur length in addition to head and abdomen measurements. *Radiology* 1984; 150:535–540.
36. Hadlock FP, Harrist RB, Sharman RS, Deter RL, Park SK. Estimation of fetal weight with the use of head, body, and femur measurements: a prospective study. *Am J Obstet Gynecol* 1985; 151:333–337.
37. Deter RL, Harrist RB. Growth standards for anatomic measurements and growth rates derived from longitudinal studies of normal fetal growth. *J Clin Ultrasound* 1992; 20:381–388.
38. Owen P, Donnet ML, Ogston SA, Christie AD, Howie PW, Patel NB. Standards for ultrasound fetal growth velocity. *Br J Obstet Gynaecol* 1996; 103:60–69.

39. Phatak M, Ramsay J. Impact of maternal obesity on procedure of mid-trimester anomaly scan. *J Obstet Gynaecol* 2010; 30:447–450.
40. Benacerraf B. The significance of the nuchal fold in the second trimester fetus. *Prenat Diagn* 2002; 22:798–801.
41. International Society of Ultrasound in Obstetrics and Gynecology. Cardiac screening examination of the fetus: guidelines for performing the “basic” and “extended basic” cardiac scan. *Ultrasound Obstet Gynecol* 2006; 27:107–113.
42. Kirk JS, Comstock CH, Lee W, Smith RS, Riggs TW, Weinhouse E. Sonographic screening to detect fetal cardiac anomalies: a 5-year experience with 111 abnormal cases. *Obstet Gynecol* 1997; 89:227–232.
43. Lee W. Performance of the basic fetal cardiac ultrasound examination. *J Ultrasound Med* 1998; 17: 601–607.
44. Chervenak FA, Chervenak JL. Medical legal issues in obstetric ultrasound. *Clin Perinatol* 2007; 34: 299–308, vi.
45. Doubilet PM, Benson CB. First, do no harm . . . to early pregnancies. *J Ultrasound Med* 2010; 29: 685–689.
46. Marinac-Dabic D, Krulewitch CJ, Moore RM Jr. The safety of prenatal ultrasound exposure in human studies. *Epidemiology* 2002; 13(suppl 3):S19–S22.
47. Miller MW, Brayman AA, Abramowicz JS. Obstetric ultrasonography: a biophysical consideration of patient safety—the “rules” have changed. *Am J Obstet Gynecol* 1998; 179:241–254.
48. Sheiner E, Freeman J, Abramowicz JS. Acoustic output as measured by mechanical and thermal indices during routine obstetric ultrasound examinations. *J Ultrasound Med* 2005; 24:1665–1670.
49. US Food and Drug Administration. Fetal keepsake video. May 2011. US Food and Drug Administration website. <http://www.fda.gov/MedicalDevices/Safety/AlertsandNotices/PatientAlerts/ucm064756.htm>. Accessed June 11, 2012.